

Neurological complication after vertebroplasty using bone cement: A case report

Vu Dinh Nam¹, Do Manh Thang², Dang Viet Son², Vu Thi Phuong Thao¹

ABSTRACT

Objective: To report a rare neurological complication following percutaneous vertebroplasty through a clinical case. **Case presentations:** A case of vertebral compression fracture treated with percutaneous cement augmentation is described. After vertebroplasty, the patient developed spinal cord compression syndrome and subsequently underwent decompressive surgery with spinal fixation. Postoperative recovery was favorable. **Conclusion:** Spinal cord compression after vertebroplasty is a rare but severe complication. Careful consideration of vertebral body fracture morphology is essential when selecting patients for vertebral augmentation with bone cement in order to minimize this risk.

Keywords: *Vertebroplasty complication, middle column syndrome, spinal cord compression.*

¹ Hai Phong University of Medicine and Pharmacy, Vietnam
² Viet Tiep Hospital, Hai Phong, Viet Nam

* Corresponding author

Vu Dinh Nam
Email: vudnam@hpmu.edu.vn

Received: September 22, 2025

Reviewed: September 26, 2025

Accepted: November 1, 2025

1. Introduction

Osteoporotic vertebral compression fracture is a highly prevalent condition, particularly among the elderly. These injuries commonly affect the anterior and middle columns of the vertebral body, leading to kyphotic deformity or vertebral body collapse, often accompanied by posterior wall or pedicle disruption. Progressive bone loss in the cancellous and cortical bone may widen existing fracture lines. Vertebral augmentation using bone cement is generally effective in restoring vertebral height, reestablishing vertebral column alignment by bridging fractured trabeculae, thereby improving axial load-bearing capacity and preventing further collapse.

However, when middle column fractures are large, and the augmentation technique fails to restore alignment between vertebral segments, vertebral fragmentation may occur. Incomplete cement interdigitation with the middle column may allow posterior displacement of fragments, resulting in severe spinal cord compression—posing challenges for postoperative management.

We present a case involving spinal cord compression following vertebral augmentation using bone cement at the Department of Neurosurgery, Viet Tiep Friendship Hospital.

2. Case report

Clinical findings:

An 80-year-old female presented with progressive back pain. She had undergone percutaneous balloon-assisted vertebroplasty. Initial postoperative course was favorable with pain relief and ambulation regained after two weeks. Subsequently, she developed recurrent back pain and gradually worsening bilateral leg weakness. Upon readmission, clinical examination revealed:

- Severe back pain (VAS 7)
- Positive spinal syndrome: localized pain, restricted spinal mobility, paraspinal muscle spasm

- Positive spinal cord compression syndrome: bilateral lower limb weakness (muscle strength 3/5)
- Reduced deep tendon reflexes
- No sensory deficits
- Urinary incontinence
- No signs of infection

Paraclinical investigations:

X-ray: Grade 3 compression fracture at L1, kyphotic angle of L1 = 4.3° , D12–L2 = 18.1° . Fracture line through mid-vertebral body with inadequate cement filling between anterior and middle columns. Posterior displacement of the middle column causing significant canal narrowing.

CT scan: Fracture gap > 4 mm separating anterior and middle columns. Posterior migration of middle column with void cement space and severe spinal canal stenosis.

MRI: No signs of osteomyelitis at L1; intervertebral discs were intact.

Electromyography (EMG): L1 nerve root compression identified.

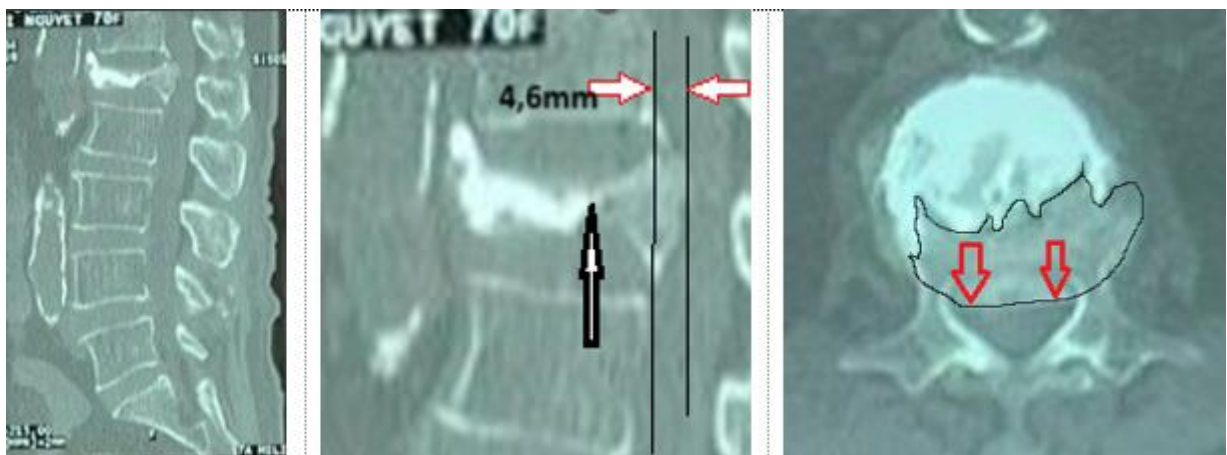


Figure 1. CT imaging showing grade 3 L1 compression fracture. The middle column is disconnected from the anterior column at the black arrow, posterior displacement of the middle column by 4.6 mm (red arrow), causing canal stenosis.

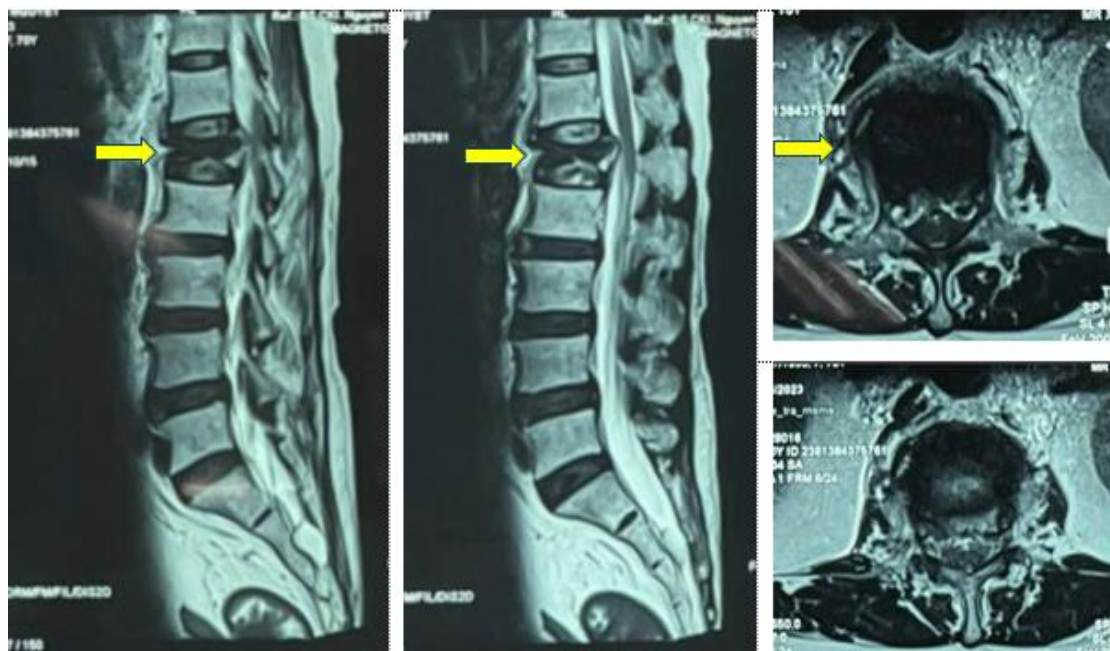


Figure 2. *Sclerotic fracture line and posterior wall compressing the spinal cord on MRI (yellow arrow); no posterior longitudinal ligament hypertrophy*

Diagnosis:

Spinal cord compression syndrome secondary to L1 compression fracture (OF4, Malgal 2) with osteoporosis, post-vertebroplasty using bone cement.

Treatment:

The patient underwent posterior decompression at L1 with pedicle screw fixation and cement augmentation from T10 to L3. Postoperatively, motor strength improved, back pain decreased, and signs of cord compression resolved. Vital signs remained stable. Follow-up radiographs showed improved vertebral alignment with corrected kyphotic angle (D12–L1 = 4.3°).




Figure 3. *Minimally invasive surgery (MISS): posterior decompression and kyphosis correction using cement-augmented pedicle screws*

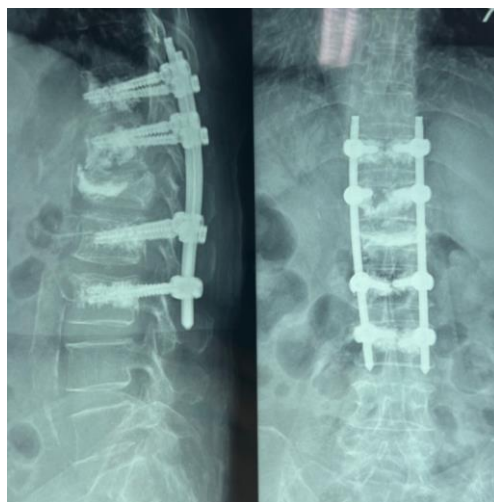

Figure 4. *Postoperative X-ray showing pedicle screw fixation from D11 to L3 and improved sagittal alignment of D12-L1 4,3°.*

3. Discussion

Although vertebroplasty is minimally invasive with generally few complications—mostly related to cement leakage—one rare but serious complication is failure to achieve adequate anterior-middle column integration. In such cases, posterior migration of the middle column can lead to spinal canal stenosis. This risk increases with comminuted fractures or Malgal A2-type fractures with vertebral clefts > 3 mm. Balloon inflation and cement injection

may widen fracture gaps.

Harrington (2001) reported cement leakage into the spinal canal and foramina causing immediate neural compression, persistent pain, and urinary incontinence. The mechanism may involve both mechanical compression and chemical injury from polymerization heat [1].

Tsai et al. (2003) reported posterior cement migration causing cord compression that required surgical decompression for neurological recovery [2].

Patel (2007) found that 3 out of 14 patients developed neurological complications due to progressive fracture instability. In 2 cases, posterior displacement of middle column fragments occurred due to loss of columnar integrity detected 3 months post-op [3].

Lee suggested that balloon inflation during vertebral augmentation may cause posterior bone fragment migration [4]. Clinical manifestations vary depending on the spinal level involved.

Hiwatashi reported that in 21 patients with <4 mm posterior fragment migration, no neurological complications occurred, but recommended using contrast-enhanced myelography during balloon inflation to monitor posterior displacement.

Though neurological complications are rare, they can cause severe disability. Vertebral augmentation should be reserved for patients unresponsive to conservative therapy and able to tolerate procedural risks.

"Ceiling zone" concept: Distefano introduced the term “ceiling zone” to describe areas not adequately filled with cement post-vertebroplasty, suggesting that bridging devices may be needed to prevent posterior migration of the middle column [5].

Case-specific analysis: In our patient, a vertebral cleft >3 mm and large anterior column kyphosis were identified retrospectively. Overemphasis on vertebral height restoration without ensuring columnar integration, combined with high balloon pressure during inflation, likely led to unnoticed posterior middle column displacement and subsequent spinal stenosis.

Surgical correction strategy: Most authors recommend early decompression upon detecting neurological deficits, combined with instrumentation to restore spinal alignment and, if feasible, remove cement fragments. Neurological recovery is typically rapid post-decompression.

Implant choice: Using bridging implants helps interconnect vertebral columns and prevents posterior migration of the middle column. If >4.5 mm posterior wall displacement is detected during balloon inflation, balloon pressure and cement viscosity should be reduced. Cement should be injected slowly to infiltrate trabecular bone and form stable intercolumnar bonds. These devices ensure column stability without compromising height restoration.

4. Conclusion

Patient selection for vertebral augmentation must consider fracture morphology. Fracture clefts >3 mm and potential for middle column displacement should be identified to prevent neurological complications. Balloon pressure and cement viscosity must be optimized to avoid widening the fracture gap. If columnar dissociation is detected during the procedure, adjunctive devices should be employed to enhance stability and prevent posterior migration.

Recommendation: To avoid neurological complications during cement injection, surgeons should exercise caution in patients with multiple fracture lines within the vertebral body. The cement injection step should be performed very slowly under C-arm guidance. For

patients with complex fracture patterns, alternative interventions such as spinal fixation with pedicle screws or neural decompression should be considered.

Acknowledgements

The authors thank patients and colleagues who kindly supported this study.

Conflict of interests

The authors declare that there is no conflict of interest regarding the publication of this article.

Sources of funding

None.

Consent

Written informed consent was obtained from the patient for publication of this case report and accompanying images. A copy of the written consent is available for review by the Editor-in-Chief of this journal on request.

REFERENCES

1. Harrington K. (2001). Major neurological complications following percutaneous vertebroplasty with polymethylmethacrylate: A case report. *J Bone Joint Surg Am*, 83:1070–1073.
2. Tsai TCW, Lai P. (2003). PMMA cement dislodgement following percutaneous vertebroplasty: A case report. *Spine*, 28:E457–E460.
3. Patel AA, Harrop JS, Gelb DE. (2007). Neurologic deficit following percutaneous vertebral stabilization. *Spine*, 32(16):1728–1734.
4. Lee YH, Chen PQ, Wu CT. (2022). Delayed-onset radiculopathy caused by retropulsed bone fragment after percutaneous kyphoplasty: Four case reports. *BMC Musculoskeletal Disorders*, 23(1):529.
5. Distefano D, Scarone P, Isalberti M. (2020). The Armed Concrete Approach: Stent-screw-assisted internal fixation (SAIF) reconstructs and internally fixates the most severe osteoporotic vertebral fractures. *Journal of NeuroInterventional Surgery*, 0:1–7.
6. Ratliff J, Nguyen T, Heiss J. (2001). Root and spinal cord compression from methylmethacrylate vertebroplasty. *Spine*, 26:E300–E302.
7. Aebi M, Maas C, Treuheim TDP. (2018). Comparative biomechanical study of a new transpedicular vertebral device and vertebroplasty. *Clinical Biomechanics*, 56:40–45.
8. Kettler A, Schmoelz W, Shezifi Y. (2018). Biomechanical performance of the BeadEx implant for osteoporotic fractures: Restoration and maintenance of height and stability. *Clinical Biomechanics*. DOI: S0268003318302171.